Brain structure change in Posttraumatic Stress Disorder: A combined surface- and voxel-based study

Sheeva Azma[1], Rachel Thompson[2], Diana Bermudez[3], Rachael Renton[1], Adebanke Adeyemo[1], James Meyerhoff[3], Richard Amdur[4,3], Bonnie Green[3], Mary Ann Dutton[3], John VanMeter[1]

[1]Center for Functional and Molecular Imaging, Georgetown University Medical Center, Washington, DC, [2]The Catholic University of America, Washington, DC, [3]Center for Trauma and the Community, Department of Psychiatry, Georgetown University Medical Center, Washington, DC, [4]Research Service, VA Medical Center, Washington, DC

INTRODUCTION

Studies examining gray matter (GM) change in Posttraumatic Stress Disorder (PTSD) have been limited to separate analyses using either voxel-based morphometry (VBM) or surface-based cortical thickness (CT) approaches. Since VBM is sensitive to multiple changes in GM such as thickness, volume, and cortical folding, the use of cortical thickness measurements combined with VBM may provide multi-modal validation of PTSD-related brain structure alterations. This study combines surface- and voxel-based approaches in correlating PTSD symptom severity with GM, in brain regions previously found to exhibit GM decrease in patients versus controls.

METHODS

11 PTSD patients (females, mean age 39.4 yrs), with least one occurrence of a traumatic event since age 18, were assessed using a number of neuropsychiatric instruments. PTSD symptom severity was assessed with the PTSD Checklist (PCL) (Weathers, 1993). Individuals with current substance dependence, lifetime or current psychosis, bipolar disorder, current suicidality, and current psychoactive medications, were excluded. A T1-weighted 3D MPRAGE volume was used in analyses (Siemens 3T Tim Trio Scanner, 176 sagittal slices, TR/TE=1900/2.52ms, effective resolution 1mm^3).

Voxel-Based Morphometry: T1 volumes were processed using SPM5 (Ashburner, 2000). Individual volumes were normalized and segmented into tissue type. Gray matter segmentations were then modulated, and smoothed with a 12mm Full-Width Half-Maximum Gaussian kernel (FWHM).

Cortical thickness: T1 volumes were processed using Freesurfer (Dale, 1999; Fischl, 1999a-b), including alignment to MNI305 template, bias correction, skull stripping, and segmentation into tissue types. Cortical thickness was computed and parcellated with an automatic segmentation procedure. Thickness measures were smoothed using a FWHM of 10mm.

To test association between GM changes and PTSD severity, multivariate regression was performed on both cortical thickness and VBM data, using current PCL score as a correlate and age as covariate-of-no-interest. *t*-statistic maps were thresholded at p<0.01 uncorrected at the whole-brain level, with minimum cluster size of 10 voxels for VBM, and 10 mm^2 for cortical thickness.

RESULTS: VOXEL-BASED MORPHOMETRY ANALYSIS

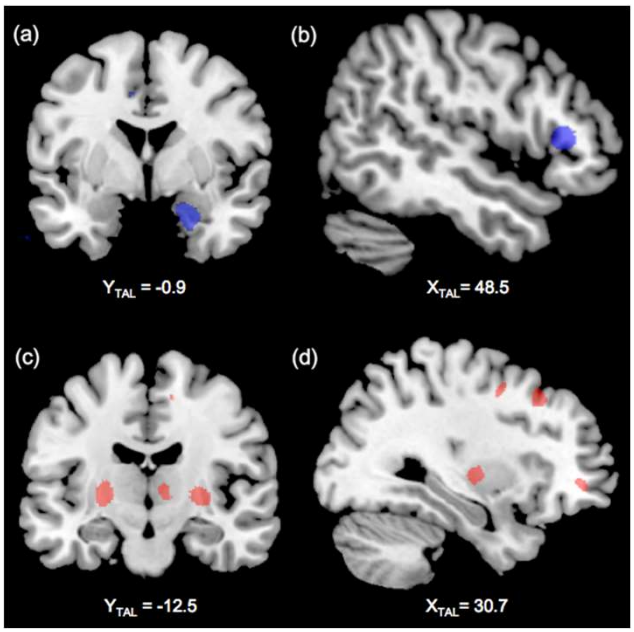

Figure 1. VOXEL-BASED MORPHOMETRY (VBM): Decreases in gray matter associated with increasing PTSD severity (i.e. PCL score) were observed in (a) right parahippocampal gyrus and (b) right inferior frontal gyrus (BA45). Positive correlations between GM volume and PTSD severity were observed in regions of (c) bilateral globus pallidus, right medial dorsal nucleus of the thalamus, and (d) right mid-frontal gyrus (BA8). Results are displayed at p<0.01, uncorrected, whole-brain level.

RESULTS: CORTICAL THICKNESS ANALYSIS

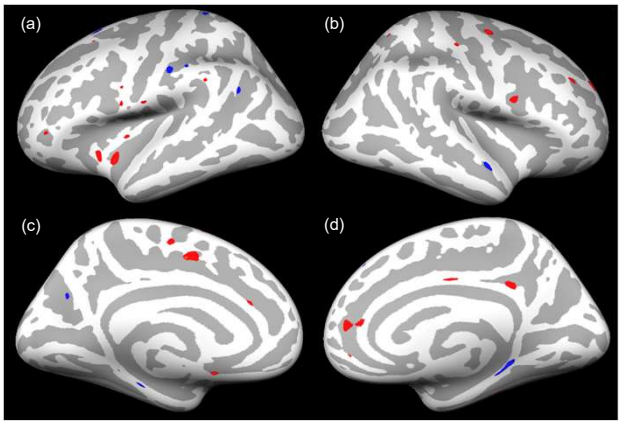

Figure 2. CORTICAL THICKNESS: Cortical thickness analysis identified several brain regions exhibiting PTSD-related changes in gray matter, which are displayed on lateral (a, b) and medial (c, d) cortical surfaces of an averaged, inflated brain. Decreased cortical thickness was associated with PTSD severity in bilateral parahippocampal cortex; left postcentral, inferior parietal, and superior frontal cortices; left precuneus; and right superior temporal cortex. PTSD severity correlated positively with PTSD severity in bilateral superior frontal, precentral, and rostral middle frontal cortices; left insula; and right cingulate and lateral orbitofrontal cortex. Results are displayed at p<0.01, uncorrected, whole-brain level.

RESULTS: COMPARISON OF CORTICAL THICKNESS AND VBM IN PARAHIPPOCAMPAL GYRUS

Table 1. Talairach coordinates for PTSD-associated decreases in the parahippocampal gyrus. The parahippocampal gyrus showed a negative correlation between gray matter volume/thickness and PTSD severity in both analyses.

	Talairach Coordinates	
	Left Hemisphere	Right Hemisphere
Voxel-Based Morphometry	--	(18.8, -0.9, -18.5)
Cortical Thickness	(-21.0, -25.7, -16.2)	(19.9, -33.0, -7.0)

CONCLUSIONS, REFERENCES, AND SUPPORT

This study presents preliminary evidence of concordance between surface-based and voxel-based approaches to examine disease-associated GM change in PTSD. Our results extend prior findings of decreased cortical thickness in the parahippocampal gyrus (Woodward, 2009). The parahippocampal gyrus, involved in episodic memory encoding and retrieval, is thought to be disrupted in PTSD (e.g. in misperception of safe vs. threatening contexts), and is connected to the adjacent hippocampus, which has been previously shown to be volumetrically decreased in PTSD compared to healthy controls (Rauch, 2006). Results from prior GM studies have been mixed. A study of female PTSD patients versus controls reported no difference in cortical thickness and subcortical volume (Landré, 2010). The lack of group differences in this study could be due to variability within the PTSD group related to symptom severity. A study of males with combat-related PTSD, compared to controls, showed atrophy in cortical areas beyond the parahippocampal gyrus (Woodward, 2010). However, neither of these studies examined PTSD severity. Our results provide preliminary support for the idea that a disruption in memory (Rauch, 2006; Milad, 2009) with possible concomitant decrease in top-down contextual processing may be associated with PTSD severity.

References:

1. Ashburner, J., et al. (2000), 'Voxel-Based Morphometry – The Methods', Neuroimage, vol. 11, no. 6, pp. 805-821.
2. Dale, A.M., et al. (1999), 'Cortical Surface-Based Analysis I: Segmentation and Surface Reconstruction', Neuroimage, vol. 9, no. 2, pp. 179-194.
3. Fischl, B., et al. (1999a), 'Cortical surface-based analysis II: inflation, flattening, and a surface-based coordinate system', Neuroimage, vol. 9, no. 2, pp. 195-207.
4. Fischl, B., et al. (1999b), 'High resolution intersubject averaging and a coordinate system for the cortical surface', Human Brain Mapping, vol. 8, no. 4, pp. 272-284.
5. Landré, L., et al. (2010), 'Preserved subcortical volumes and cortical thickness in women with sexual abuse-related PTSD', Neuroimage, vol. 183, no. 3, pp. 181-186.
6. Milad, M.R., et al. (2009), 'Neurological basis of failure to recall extinction memory in posttraumatic stress disorder', Biological Psychiatry, vol. 66, no. 12, pp. 1075-1082.
7. Rauch, S.L., et al. (2006), 'Neurocircuitry models of posttraumatic stress disorder and extinction: human neuroimaging research – past, present, and future', Biological Psychiatry, vol. 60, no. 4, pp. 376-82.
8. Weathers, F., et al. (1993), 'The PTSD Checklist (PCL): Reliability, Validity, and Diagnostic Utility', Annual Meeting of International Society for Traumatic Stress Studies, San Antonio, TX.
9. Woodward, S.H., et al. (2009), 'Smaller global and regional cortical volume in combat-related Posttraumatic Stress Disorder', Archives of General Psychiatry, vol. 66, no. 12, pp. 1373-1382.

Support: NIH P20MH068450 and P20RR023501.